

*Crossover replantation as a salvage procedure following bilateral transhumeral upper limb amputation: a case report*

**Archives of Orthopaedic and Trauma Surgery**

Including Arthroscopy and Sports Medicine

ISSN 0936-8051

Volume 131

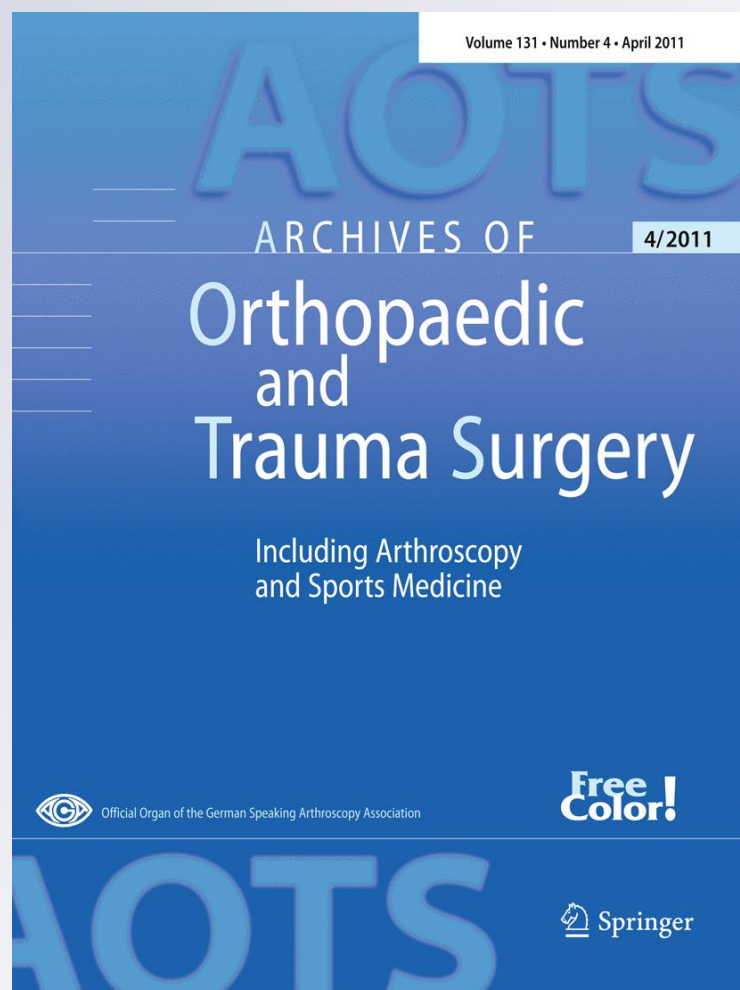
Number 4

Arch Orthop Trauma Surg

(2011) 131:567-572

DOI 10.1007/s00402-010-1217-

x



**Your article is protected by copyright and all rights are held exclusively by Springer-Verlag. This e-offprint is for personal use only and shall not be self-archived in electronic repositories. If you wish to self-archive your work, please use the accepted author's version for posting to your own website or your institution's repository. You may further deposit the accepted author's version on a funder's repository at a funder's request, provided it is not made publicly available until 12 months after publication.**

## Crossover replantation as a salvage procedure following bilateral transhumeral upper limb amputation: a case report

İsmail Bülent Özçelik · Berkan Mersa ·  
Fatih Kabakaş · Bülent Saçak · Samet Vasfi Kuvat

Received: 27 July 2010 / Published online: 15 December 2010  
© Springer-Verlag 2010

**Abstract** Cross-over replantation is a salvage option for cases with bilateral extremity amputations where the wound conditions do not enable an orthotopic replantation. Here, we present a 24-year-old patient who applied to our center with bilateral transhumeral amputations. Due to the wound conditions, a cross-over replantation was performed. 24 months after the initial operation, the patient exhibits good protective sensation at the distal levels and function to some degree, whereas the active range of motion is not as promising as previously expected. In this article, we present this case together with its immediate and long-term outcomes and the consequences of the cross-over replantation.

**Keywords** Cross-over replantation · Transhumeral amputation · Arm

### Introduction

Advances in microsurgery rendered replantation surgery a routine procedure for hand centers [1]. Major replantation of proximal level amputations are considered to be more challenging because of the potential risks of failure and the local or more importantly systemic complications. In circumstances where gross contamination and/or severe destruction of the proximal stump exclude the possibility of immediate and orthotopic replantation, temporary ectopic

replantation may be the most appropriate salvage procedure [2].

Bilateral extremity amputations are even further challenging: in cases of exceptional bilateral amputations with inappropriate wound conditions, crossover replantations have been successfully performed on both upper and lower limb amputations [3–7]. To our knowledge, the most proximal crossover replantation at the upper limb was reported by Reagan and Reagan [8], with a successful replantation 8 cm proximal to the wrist.

The patient subject to this report is a 24-year-old who presented with severe crush injury and bilateral proximal transhumeral amputations, with one limb salvaged by cross-over replantation.

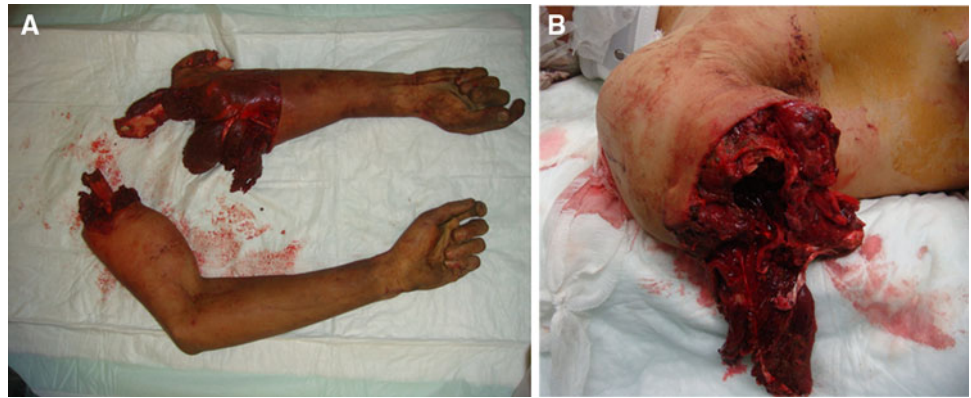### Case report

A 24-year-old man was referred to our department about 3 h after an injury caused by an industrial axle device used for agricultural purposes. He was severely injured with bilateral proximal transhumeral amputations (Fig. 1). Resuscitation and emergency principles were expeditiously performed by the resuscitation team. When the patient was admitted to the hospital, his hemoglobin value was 6 g/dl and his haematocrit was 17%. Following an endotracheal intubation, 13 units of packed red blood cells and 5 units of plasma were rapidly transfused together with adequate colloids.

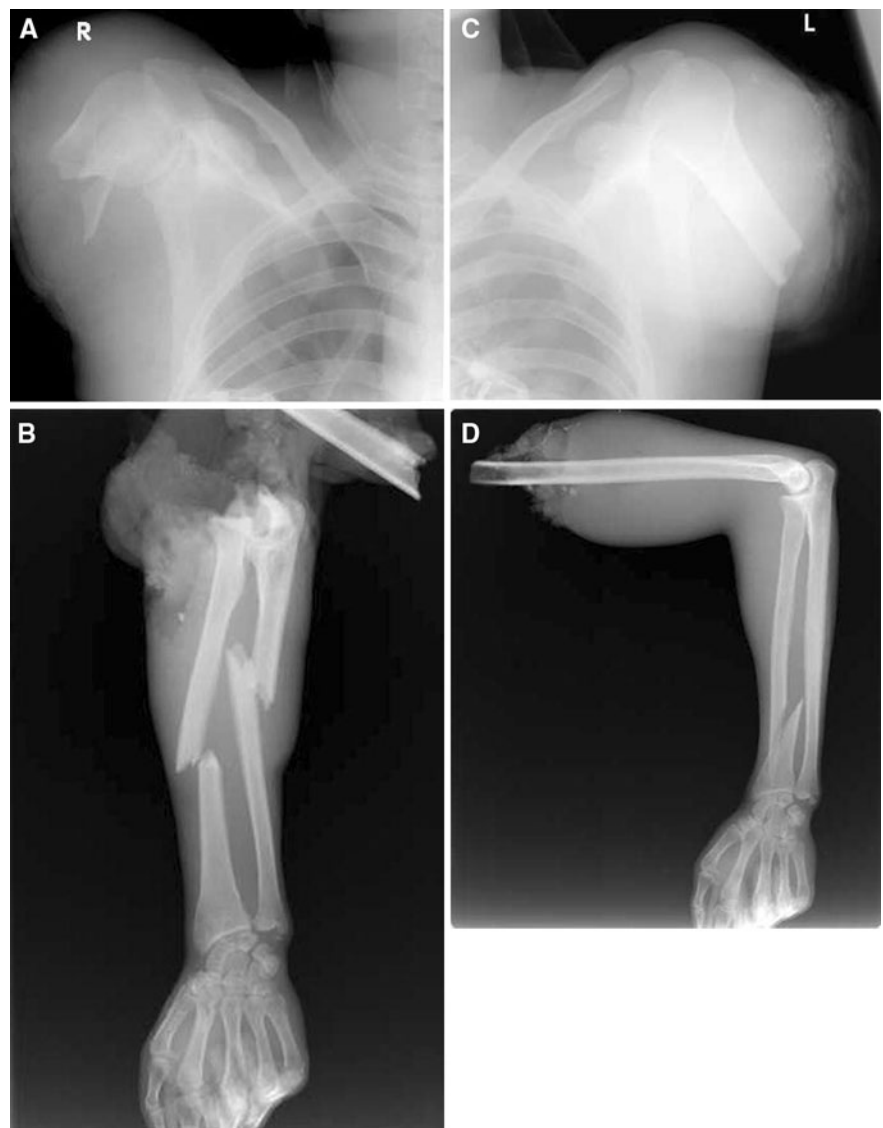
In the operation room settings, the patient was evaluated by the hand surgery team at the ninth hour of the injury. The right arm showed extensive crush injury and severe avulsion-type amputation. At the distal segment, the fractured dislocation of the elbow joint, multiple fractures below the elbow level, and severe avulsion of the soft

İ. B. Özçelik (✉) · B. Mersa · F. Kabakaş · B. Saçak ·  
S. V. Kuvat  
IST-EL Hand Surgery, Microsurgery and Rehabilitation Group,  
Gaziosmanpasa Hospital, Istanbul, Turkey  
e-mail: bulent-ozcelik@hotmail.com

**Fig. 1** **a** The right arm was injured extensively at the amputation level, so the left arm was relatively more appropriate for a possible replantation. **b** The proximal stump of right arm was evaluated as suitable for replantation



**Fig. 2** X-ray images of stumps and amputated arms of **a**, **b** right and **c**, **d** left sides



tissues were noted (Fig. 2). However, the proximal stump of the right limb was evaluated as appropriate for a replantation procedure (Fig. 1b). On the left side, the arm was amputated at a higher level near to the glenohumeral

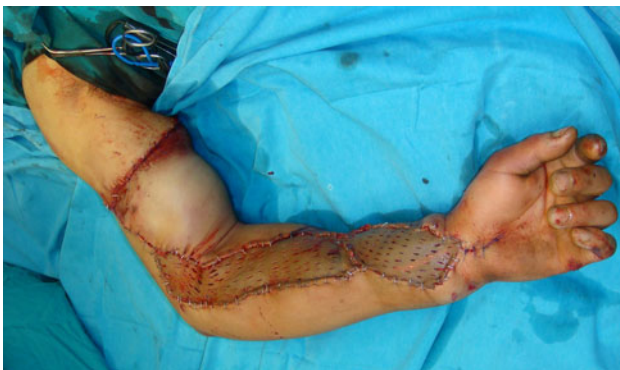joint. The amputated segment was in relatively better condition compared to the contralateral arm. Despite a diaphyseal fracture of the radius, the distal segment was assessed as appropriate for a replantation procedure

(Fig. 2d). On the other hand, the proximal stump was severely crushed, with a short bone segment while the deltoid, latissimus dorsi and pectoralis major muscles were noted as severely avulsed and detached from their insertions over the humerus. Further dissection exposed a brachial plexus avulsion at the cord level together with a brachial artery avulsion.

At this point, it has been decided that neither of the limbs was suitable to perform a regular replantation. In order to preserve a limb, to achieve a limb of adequate length for a below-elbow prosthesis application in the long run, a crossover replantation of the relatively better preserved left arm to the right limb stump was planned. In this case, the MESS [9] score can be taken as 7, the NISSA [10] score 11 and the HFS-98 [11, 12] score can be taken as 15 (for right limb stump and left arm).

After a rapid debridement, the main vessels and nerves were identified and tagged. Following the shortening of the distal segment for about 10 cm, two bone ends were fixed with an osteosynthesis plate and screws. The brachial artery was anastomosed directly without the need of vein transposition, allowing reperfusion at the 11th hour of the injury. Cephalic, basilic and two other superficial veins were anastomosed to provide venous drainage. Musculo-cutaneous, median, radial and ulnar nerves were coapted with the counterparts directly without any nerve grafts. The operation was extended with a forearm fasciotomy combined with a dorsal hand fasciotomy (Fig. 3).

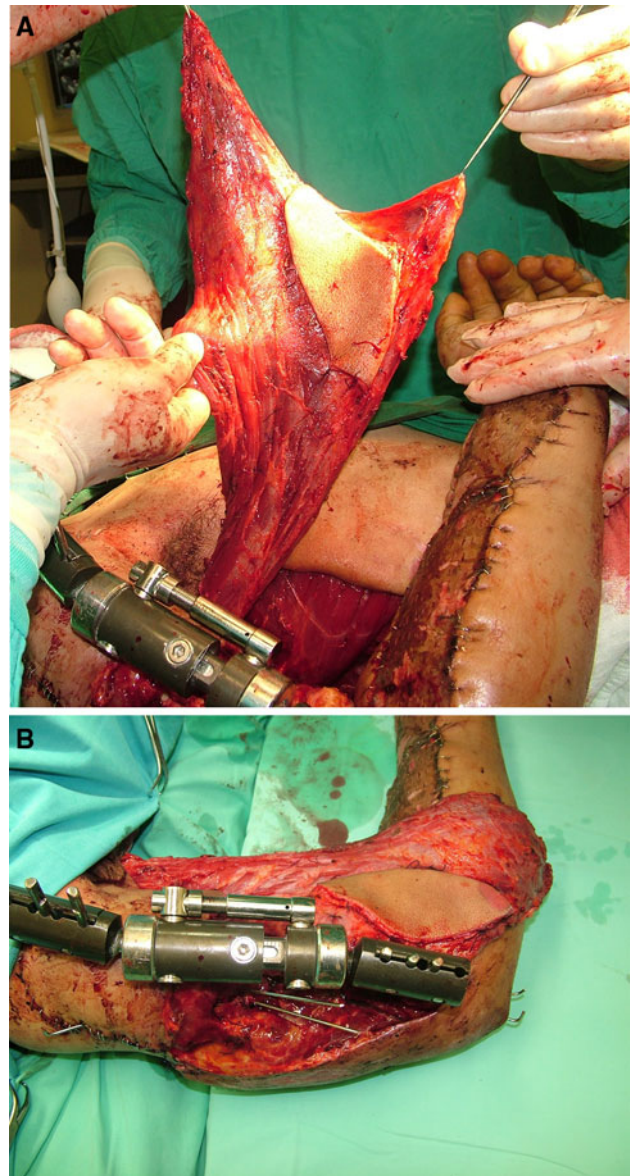The total ischemia time was noted as 11 h and the total surgery time was 8.5 h. The patient's vital signs and right limb revascularization were continuously monitored. Most of the vital and clinical parameters stayed within the normal range during the early post-operative days. At the 9th post-operative day, signs of a purulent infection were noted. The specimens revealed a pseudomonas infection. At the 11th post-operative day, muscle and skin necrosis was evident over the biceps region. After serial debridements and



**Fig. 3** Appearance of the extremity immediately after the cross-over replantation. Fasciotomy defects are covered with split thickness skin grafts, harvested from the amputated extremity

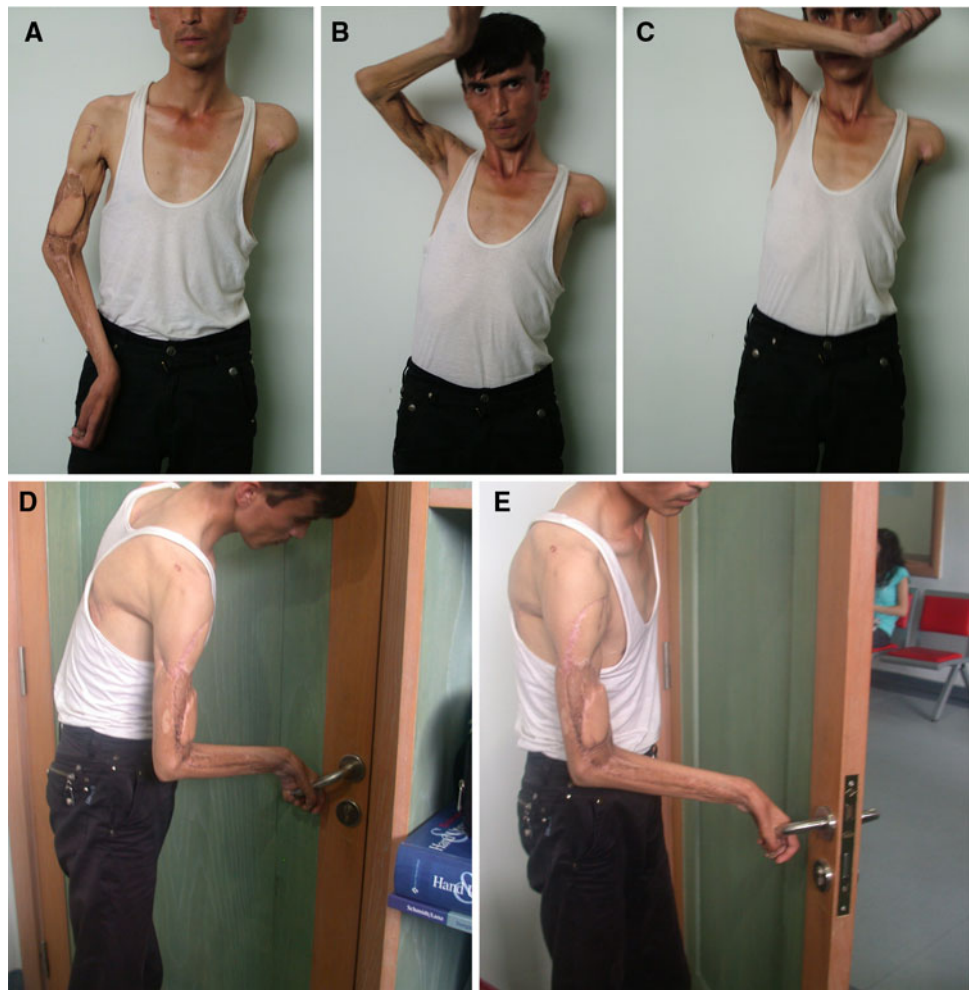an appropriate antibiotherapy regimen, on the 17th post-operative day, the plates were replaced with an external fixation device. Ulnar nerve detachment was reconstructed with a 5 cm sural nerve graft in three slips. The pedicled latissimus dorsi was harvested and transposed to the area for both tissue coverage and to restore biceps muscle function (Fig. 4). Split thickness skin grafting was performed to cover the muscle.

Subsequently, there were no major circulatory or soft tissue problems. A splint was applied with the elbow at 100° of flexion and the forearm at maximum supination. The patient was discharged at the 26th postoperative day. During discharge, the patient's hemoglobin value was



**Fig. 4** Pedicled latissimus dorsi muscle transfer was performed simultaneously with the substitution of osteosynthesis plates with an external fixation device

**Fig. 5 a–c** After 24 months of post-operative follow-up, the patient can show flexion in the shoulder joint, but has limited motion at the elbow joint. **d, e** The patient is comfortable to do daily basic activities such as opening a door



10 g/dl and his haematocrit was 29%. Gentle passive exercises were started as soon as the splint was removed and continued at home after the patient was discharged.

At the eighth month of the follow-up period, pseudoarthrosis was diagnosed and the patient was re-operated to replace the external fixation device with plate and screw osteosynthesis, combined with cancellous bone grafting.

By the end of 24 months, the patient had a favourable return of sensation reaching to the level of wrist, particularly over the median and radial nerve territories. The two-point discrimination distance was 12 mm in the distal of the forearm, close to the wrist. The protective sensation was not present in the whole of the hand. At this stage, good bony union was observed at the humeral fracture site. The shoulder joint presented close to 90° of active flexion, while the elbow joint presented a limited active flexion with 20° of active flexion and 40° of passive range of motion (Fig. 5a, b). The passive range of motion in the wrist was 30° while the active flexion was 10°; however, there was absolutely no active flexion or extension of the fingers. At this time, considering the relatively poor

outcome and adhering to the initial surgical intention, the patient was informed about and offered a below-elbow amputation and the appliance of myoelectrical forearm prosthesis. Nevertheless, already capable of basic daily activities such as opening doors etc., the patient was satisfied with the outcome and refused any further operations (Fig. 5c, d). The functional outcome according to Chen's criteria was on medium level [13].

## Discussion

Chinese surgeons deserve credit for the first successful examples of crossover replantation in the 1970s, as reported by Malt and McDowell [14]. Since then, although there have been reports of crossover replantations, these were limited in number [3–15]. There are very few circumstances to consider and perform a crossover replantation. First of all, damage to both extremities must have occurred. In such cases, a crossover replantation can only be performed if orthotopic replantation is a non-option

and the remaining tissues are convenient for a crossover replantation. The procedure is unusual, technically demanding and chosen to rescue at least one limb which may function in varying degrees. Regarding the lower extremities, it has been more than two decades since a crossover replanted foot combined with a prosthetic device is admitted to be more functional than two artificial limbs [16]. For the upper extremities, a similar result was presented and advocated by Peacock and Tsai [17], introducing the functional results of a bilateral proximal humeral amputation, treated by replantation at one side and body-powered prosthesis on the other. It was briefly shown that the replanted side had a better functional outcome in terms of strength, range of motion and sensory return. Even though the case was an orthotopic replantation, it is an important case to predict if any crossover replantation would produce better outcomes. Yet, there have been very few successful crossover upper extremity transfers [3–5, 8].

To our knowledge, there are no references in the literature mentioning a similar case of crossover replantation at such a high level above the elbow. Replantation of a high-level amputation is controversial by itself. Factors such as ischemia time, age, associated injuries and the degree of the tissue damage must be carefully considered. The only successful case of bilateral replantation above the elbow level was presented by Koul et al. [18]. As the patient was 6 years old, the authors emphasized the generally better outcome of replantation in children.

In our case, the loss of the tissue of significant importance at different levels made an orthotopic replantation impossible for either sides. However, a cross-arm transfer was decided to preserve the relatively better preserved and salvageable left-sided amputate. In any crossover replantation attempts over the wrist, one of the major concerns is the new and unfamiliar orientation of the thumb. Despite such limitations, there are good examples of functioning 'reverse' thumbs [8]. Overall, we believe that in the case of a successful crossover replantation followed by the patients' discordance, the surgeon may electively amputate the limb distally, providing opportunity for a more distal prosthesis than the initial injury would dictate. Patients who underwent below-elbow amputations are shown to benefit from any prosthesis significantly more than the above-elbow amputation patients fitted with prostheses [19].

A wide variety of soft tissue defects may be presented following upper arm divisions involving traction, avulsion or crush injuries. Pedicled latissimus dorsi muscle transfer is regarded as a good option not only to provide soft tissue coverage, but also to restore elbow flexion [20]. Despite the good results of elbow flexion in the literature obtained with the latissimus transfer, we did not achieve an adequate

active flexion range. This is thought to be due to many factors such as the ischemia time, delayed bone healing, severity of the injury and the lack of patient collaboration for rehabilitation.

The MESS [9], NISSSA [10] and HFS-98 [11, 12] scoring methods were used to guide the decision whether to amputate or to reconstruct. In 1990, Helfet et al. [9] described the Mangled Extremity Severity Score (MESS) method for lower extremity injuries based on the skeletal/soft-tissue injuries, limb ischemia, shock and age parameters. In this method using a scale between 1 and 14, shock and age are rated with a score of 0–2 each, skeletal/soft tissue injuries with a score of 1–4 and limb ischemia is rated with a score of 0–3 (score doubled for ischemia > 6 h). Helfet et al. stated that an amputation is indicated for MESS scores  $\geq 7$  on this scale. The NISSSA was described by McNamara et al. [10] in 1994. The most important difference of the NISSSA scoring from the MESS scale is that it also takes nerve injuries into consideration. In the NISSSA scale, the indication for amputation is 11 points and above. The Hannover Fracture Scale-98 (HFS-98) has been defined in 1982 [11] and modified in 2001 [12]. Like the ones mentioned above, this scale is also based on bone loss, skin injury, muscle injury, wound contamination, periosteal stripping, local circulation, systemic circulation and nerve function parameters. The modified HFS-98 scale is evaluated over a total of 22 points and an amputation is also recommended at 11 points and above. Although the MESS, NISSSA and HFS-98 [9–12] scales are generally targeted to the evaluation of the lower extremity injuries, in our case, the MESS score can be taken as 7, the NISSSA score 11 and the HFS-98 score can be taken as 15. These values all point to the necessity of an amputation. Having said that, in this case with bilateral amputations, we were left with no other choice but giving a try to the replantation of at least one extremity.

The DASH-T scoring applied in extremity replantation cases is generally not applied in major replantations. The universally accepted scoring in the functional evaluation of major upper extremity replantation surgery is Chen's classification. According to this, the functional outcome in our case was on a medium level. In the study by Sugun et al. [21] on the functional outcomes of major upper extremity amputations due to disease, a correlation has been observed between the level and manner of the injury and Chen's criteria. Accordingly, the medium-level functional outcome in our case where the level of the injury was rather proximal is not surprising.

In conclusion, our case describes a crossover transfer following a very rarely seen bilateral transhumeral avulsion type amputation with associated multi-organ injury. Despite the prolonged hospitalization, the multi-numbered operations and the unfamiliar appearance of the final result,

this way of action is the only option as a salvage procedure in an extensive injury as in this case. Despite all functional and esthetic drawbacks, it is still worthwhile as the gain may not be duplicated with a prosthesis.

**Conflict of interest** None.

## References

- Liang K, Zhong G, Yin J, Xiang Z, Cen S, Huang F (2010) Cross-arm replantation for traumatic bilateral upper extremity amputations: a case report. *Arch Orthop Trauma Surg* (Epub ahead of print)
- Godina M, Bajec J, Baraga A (1986) Salvage of the mutilated upper extremity with temporary ectopic implantation of the undamaged part. *Plast Reconstr Surg* 78:295–299
- Kutz JE, Sinclair SW, Rao V, Carlier A (1982) Cross-hand replantation: preliminary case report. *J Microsurg* 3:251–254
- Yildirim S, Akan M, Aköz T (2003) Transmetacarpal cross-hand replantation as a salvage procedure in a case of traumatic bilateral upper extremity amputation. *Plast Reconstr Surg* 112:1350–1354
- Adkins P, Graham B, Kutz JE (1992) Functional evaluation of an emergency cross-hand replantation: a 9-year follow-up. *J Hand Surg Am* 17:214–216
- Cinar C, Arslan H, Ogur S, Pilanci O, Yucel A, Cetinkale O (2007) Crossover replantation of the foot after bilateral traumatic lower extremity amputation. *Ann Plast Surg* 58:667–672
- Kayıkçıoğlu A, Ağaoğlu G, Nasir S, Keçik A (2000) Crossover replantation and fillet flap coverage of the stump after ectopic implantation: a case of bilateral leg amputation. *Plast Reconstr Surg* 106:868–873
- Reagan DS, Reagan JM (2000) Emergency cross-arm transfer. *Plast Reconstr Surg* 106:648–652
- Helfet DL, Howey T, Sanders R, Johansen K (1990) Limb salvage versus amputation. Preliminary results of the Mangled Extremity Severity Score. *Clin Orthop Relat Res* 256:80–86
- McNamara MG, Heckman JD, Corley FG (1994) Severe open fractures of the lower extremity: a retrospective evaluation of the Mangled Extremity Severity Score (MESS). *J Orthop Trauma* 8:81–87
- Tscherne H, Oestern HJ (1982) A new classification of soft-tissue damage in open and closed fractures (author's translation). *Unfallheilkunde* 85:111–115 (in German)
- Krettek C, Seekamp A, Köntopp H, Tscherne H (2001) Hannover Fracture Scale '98-re-evaluation and new perspectives of an established extremity salvage score. *Injury* 32:317–328 (Erratum in: *Injury* 2001;32:611)
- Chen ZW, Han YL (1987) Major limb replantation. In: Urbaink JR (ed) *Microsurgery for major limb reconstruction*. Mousby, St Louis, pp 22–26
- Malt RA, McDowell F (1973) Cable from Cathay. *N Engl J Med* 238:1353
- An PC, Kuo YR, Lin TS et al (2003) Heterotopic replantation in mutilating hand injury. *Ann Plast Surg* 50:113–118
- Chen ZW, Zeng BF (1983) Replantation of the lower extremity. *Clin Plast Surg* 10:103–113
- Peacock K, Tsai TM (1987) Comparison of functional results of replantation versus prosthesis in a patient with bilateral arm amputation. *Clin Orthop Relat Res* 214:153–159
- Koul AR, Cyriac A, Khaleel VM, Vinodan K (2004) Bilateral high upper limb replantation in a child. *Plast Reconstr Surg* 113:1734–1738
- Wright TW, Hagen AD, Wood MB (1995) Prosthetic usage in major upper extremity amputations. *J Hand Surg Am* 20:619–622
- Schoeller T, Wechselberger G, Hussl H, Huemer GM (2007) Functional transposition of the latissimus dorsi muscle for biceps reconstruction after upper arm replantation. *J Plast Reconstr Aesthet Surg* 60:755–759
- Sugun TS, Ozaksar K, Ada S et al (2009) Long-term results of major upper extremity replantations. *Acta Orthop Traumatol Turc* 43:206–213